

Eosinophilic Cellulitis as a Periocular Cutaneous Reaction

Antigoni Koukkoulli^{1*}, Nikolaos Koutroumanos² and Hugo Henderson²

¹*Pantheo Eye Centre, Limassol, Cyprus*

²*Department of Ophthalmology, Royal Free Hospital, London, England, United Kingdom*

***Corresponding Author:** Antigoni Koukkoulli, Pantheo Eye Centre, Limassol, Cyprus.

Received: November 28, 2020

Abstract

Eosinophilic cellulitis is an inflammatory dermatosis that is often misdiagnosed as infectious cellulitis due to its similar clinical presentation. The present case report is intended to raise awareness and to aid diagnosis and treatment of this uncommon condition.

A 54-year-old male presented with rapidly progressive periocular rash. Initial diagnosis of bacterial cellulitis was made and the patient was treated accordingly. There was poor response to intravenous antibiotics and the patient continued to deteriorate. Tissue biopsy of the rash revealed histological findings consistent with eosinophilic cellulitis. The clinical presentation developed soon following intravitreal bevacizumab injection and the patient described similar milder symptoms following his previous injections. On stopping his systemic antibiotics, the rash gradually resolved over a period of eight weeks.

Eosinophilic cellulitis should be part of the differential diagnosis for any cellulitis presenting with atypical features and with poor response to appropriate antibiotics.

Keywords: *Eosinophilic Cellulitis; Antibiotics; Inflammatory Dermatitis*

Introduction

Distinguishing bacterial cellulitis from its many imitators is challenging but critical if unnecessary use of antibiotics or delays in treatment are to be avoided. Eosinophilic cellulitis (EC), otherwise known as Wells' syndrome, is one such mimicker [1,2]. EC is a rare, inflammatory dermatosis that has been linked to hypersensitivity responses to different endogenous and exogenous stimuli, including medications. Pathophysiology still remains unknown, even though some regard it as a type IV hypersensitivity reaction [3]. EC is diagnosed by its clinical picture and course, and by characteristic histopathological findings [1-4]. We report a unique case of EC following an intravitreal injection.

Case Report

A 54-year-old male presented with left (OS) periocular pruritic rash which was progressive and gradually spread to involve the right eye (OD). He was a Type II diabetic and was receiving treatment for bilateral maculopathy. He denied any history of trauma, recent travel, insect bites, intravenous drug use or alteration of his regular medications. The patient was admitted under the medical team with presumed bacterial cellulitis and was commenced on intravenous co-amoxiclav 1.2g three times daily. Despite 48 hours of treatment the patient continued to deteriorate, therefore urgent imaging and ophthalmological review were organised.

Eosinophilic Cellulitis as a Periocular Cutaneous Reaction

On examination, best-corrected visual acuity was OD 6/12 and OS 6/36. There was a bilateral, periocular, non-tender, well-demarcated erythematous plaque-like rash. There were no clinical signs suggestive of orbital involvement and vital signs were normal. Systemic examination revealed no rash elsewhere in the body, no lymphadenopathy or organomegaly. Computerised-tomography (CT) demonstrated a left-sided periocular hyperdense subcutaneous infiltration resembling calcification (Figure 1). Blood investigations revealed mildly raised C-reactive protein and eosinophilia. His calcium, phosphate and parathyroid hormone levels were normal and the white cell count was not raised. In view of the atypical presentation and progressive tracking along the left face and neck, an urgent tissue biopsy was performed.

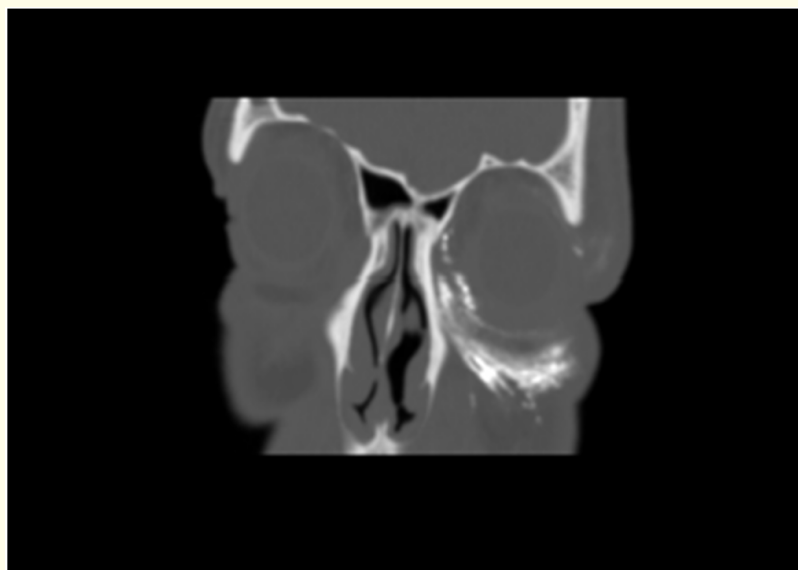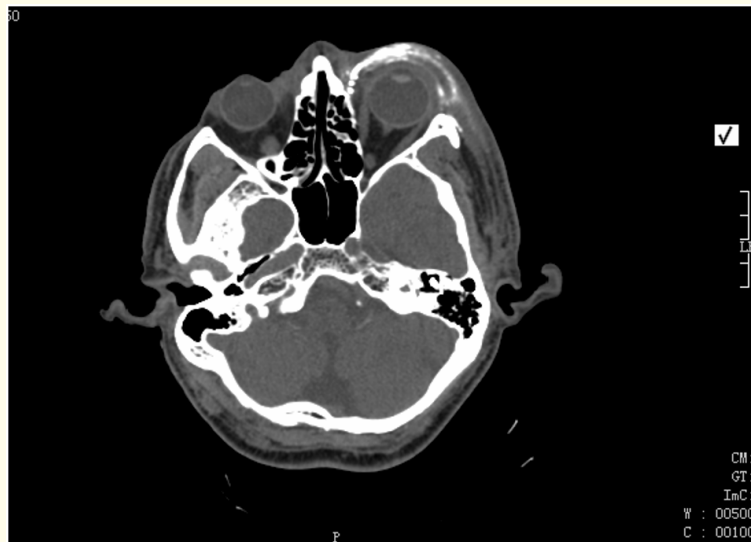


Figure 1: CT axial (1a) and coronal (1b) views demonstrating a left sided periocular hyperdense subcutaneous infiltration (white arrow). No evidence of post-septal involvement.

Eosinophilic Cellulitis as a Periocular Cutaneous Reaction

Histology showed a heavy interstitial infiltrate of eosinophils and macrophages in the dermis, dermal oedema but no vasculitis. The histopathological findings were suggestive of EC.

In view of the histology and radiological findings, systemic antibiotics were stopped. The rash gradually regressed and within eight weeks completely resolved without treatment. During later consultations, it became apparent that the rash had developed few days following his bevacizumab intravitreal injection. The patient had had similar episodes following previous injections but had all been less severe and had subsided without medical attention or treatment.

Discussion and Conclusion

Eosinophilic cellulitis was first described by GC Wells in 1971 as a recurrent granulomatous dermatitis with eosinophilia [5]. It is a rare condition with fewer than 200 cases in the literature and is often misdiagnosed as it clinically resembles infectious cellulitis.

The pathophysiology of the disease is poorly understood. In the literature there have been several descriptions of specific triggers linked to EC eruptions, both endogenous and exogenous [1-4]. Endogenous causes have included haematological disorders, lymphoproliferative malignancies and carcinomas [2]. Exogenous triggers have included insect bites, viral or bacterial infections and thimerosal-containing vaccines [2,6]. Drugs have also been implicated with 24 cases of drug-induced EC described in the literature [2]. To the best of our knowledge no report has been published so far of EC following an ocular intervention. In our patient, the EC eruptions seemed to be temporally associated with his intravitreal injections. It is very difficult to isolate the individual noxious stimulus as apart from his intravitreal injection he also had topical chloramphenicol drops post-injection and the eye was cleaned with 5% povidone iodine prior to injection. Further, the patient did not have any intraocular inflammation making bevacizumab an unlikely culprit.

The disease progresses through two clinical stages. During the acute phase the patient presents with cutaneous changes associated with pruritus or burning sensation that may precede the rash [1-4]. The skin changes can vary in appearance and severity. Our patient developed erythematous plaque-like lesions, which is one of the more common morphologies. During the resolution phase, there is gradual involution of the rash that occurs over a period of 2 - 8 weeks [1-4]. Often there are no residual skin changes but it may sometimes result in localised atrophy or hyperpigmentation [1-4]. Spontaneous resolution is often the rule, however recurrence is common.

If EC is suspected a tissue sample should be obtained. The histological findings depend on the stage of the disease. During the acute stage, there is dermal oedema associated with dermal infiltration of granulocytes of which the majority are eosinophils [1-4]. At the sub-acute stage, there are palisading groups of eosinophils and histiocytes surrounding a core of collagen containing free eosinophilic granules, known as 'flame figures' [1-4]. Flame figures are not pathognomonic to EC and are encountered in multiple other inflammatory skin conditions such as Churg-Strauss syndrome, pemphigoid, eczema and parasitic infections [1-4]. Finally, during the resolution phase there is gradual disappearance of the eosinophils, leaving histiocytes and giant cells surrounding the flame figures and foaming granulomas. Blood investigations often report normal white cell count, normal or slightly raised inflammatory markers and eosinophilia [5].

As the pathophysiology is poorly understood it is very difficult to target treatment. For cases of EC with a known underlying cause, removing the stimuli facilitates resolution [1]. Antihistamines have a role in relieving pruritus but they have no effect on the cutaneous lesions. For idiopathic cases the most common and effective treatment described has been oral steroids with a reported 92% resolution rate [1]. There have been isolated case reports suggesting a positive response with dapsone, cyclosporine, minocycline, antimalarial, psoralen with ultraviolet A therapy and topical steroids [1].

Eosinophilic Cellulitis as a Periocular Cutaneous Reaction

Given its rarity and that EC is very often misdiagnosed, several authors have attempted to clarify its diagnosis by recommending algorithms and diagnostic criteria [1,2]. We believe that a high index of suspicion is warranted in patients suspected of infectious cellulitis not responding to conventional treatment.

Financial Support

None.

Conflict of Interest

No conflicting relationship exists for any author.

Bibliography

1. Sinno H., *et al.* "Diagnosis and the management of eosinophilic cellulitis (Wells' syndrome): A case series and literature review". *The Canadian Journal of Plastic Surgery* 20.2 (2012): 91-97.
2. Heelan K., *et al.* "Wells' syndrome (eosinophilic cellulitis): Proposed diagnostic criteria and a literature review of the drug-induced variant". *Journal of Dermatological Case Reports* 4 (2013): 113-120.
3. Bansal M., *et al.* "Wells' syndrome". *Indian Dermatology Online Journal* 3.3 (2012): 187-189.
4. Gandhi R., *et al.* "Wells Syndrome (Eosinophilic cellulitis): A clinical imitator of bacterial cellulitis". *The Journal of Clinical and Aesthetic Dermatology* 4.7 (2011): 55-57.
5. Wells GC. "Recurrent granulomatous dermatitis with eosinophilia". *Transactions of the St. John's Hospital Dermatological Society* 57 (1971): 46-56.
6. Boura P., *et al.* "Eosinophilic cellulitis (Wells' syndrome) as a cutaneous reaction to the administration of adalimumab". *Annals of the Rheumatic Diseases* 65 (2006): 839-840.

Volume 12 Issue 3 March 2021

© All rights reserved by Antigoni Koukkoulli., *et al.*